

Bioceramic technology – the game changer in endodontics

Dr Ken Koch and Dr Dennis Brave take a look at the increased use of bioceramic technology in endodontics, what they believe is changing the game as we know it

Recently, we have seen a great rush to condemn teeth and place implants among both general dentists and specialists. While these recommendations may be somewhat questionable, we want all clinicians not to forget the many benefits that well done endodontics can bring to their patients. Furthermore, this desire to have dentists understand the benefits of good endodontics is critical to having the natural tooth remain a key component of restorative dentistry.

Fortunately, over the past two decades, new techniques and technology have been developed that allow the majority of dentists to perform better endodontics. Significant among these changes is the introduction of advanced material science. However, we have only recently witnessed significant changes in endodontic material science. The good news is that the arena of endodontic material science is continuing to evolve and, in fact, the game has changed. The game changer is the increased use of bioceramic technology in endodontics; more specifically in endodontic obturation.

It has been a continuing goal of Real World Endo to develop products and techniques that will deliver excellent endodontic results in the most efficient manner. Furthermore, it has been an additional goal to design these techniques in such a manner that the greatest majority of practitioners will be able to perform these procedures successfully and in a predictable manner (www.realworldendo.com). The basic EndoSequence file system has given all clinicians the ability to machine predictable shapes that ultimately lead to synchronicity between the preparation and the master cone fit. Embracing this concept of synchronicity, and taking it to a more sophisticated level in obturation are sealer-based obturation systems such as the Activ GP Obturation System and EndoSequence BC Sealer (Brasseler USA, Savannah, Georgia).

Activ GP is a system which utilizes improved glass ionomer technology (both as a sealer and as a special glass ionomer coated gutta percha cone) to create a true single cone obturation. This is very significant because a true single cone technique will allow us, for the first time, to create a hermetic seal within the root canal space. A hermetic seal has been a goal of endodontics for more than 50 years. Furthermore, a true single cone technique is a method that is now clinically achievable as a result of improved material science. Most importantly, such a technique (when performed properly) will give the greatest percentage of clinicians (due to the ease of technique) the ability to produce superior obturation results (Koch, Brave, 2006).

In fact, in a study published in the *Journal of Endodontics* in 2008, Fransen et al at Baylor University

compared the sealing ability of single cone Activ GP with glass ionomer sealer to the warm vertical compaction of gutta percha with AH Plus sealer and to the warm vertical compaction of Resilon with Epiphany sealer. Their conclusion was: 'In summary, there were no statistically significant differences for any of the parameters tested between the three obturation systems tested. Based on these results, the single cone Activ GP /GI sealer system has potential as an obturation system to provide a seal comparable to that achieved with other popular obturation systems.' (Fransen et al, 2008).

Also Russell and his colleagues at Fort Bragg (US Army) conducted 'a study utilizing a fluid filtration method which showed no statistically significant difference in leakage between the Activ GP Obturation system and gutta percha (and AH Plus sealer) using a warm vertical continuous wave of condensation technique.' (Russell et al, 2007).

These two non-sponsored studies are offered as evidence that a single cone obturation technique can be very effective if performed properly and with the correct materials. However, gaining acceptance for a true single cone technique has taken a number of years and has had its challenges.

In the original pursuit of achieving a hermetic seal in endodontics, glass ionomer (Ketac Endo) was selected because of its superior biocompatibility and its physical properties. However, a problem historically with the early generations of glass ionomer, and resin sealers, was that neither method was able to develop a true monobloc. Although there were advocates on both sides of the argument, research showed that both the glass ionomer and resin sealers each had some advantages and some limitations. However, one thing that both the resin and glass ionomer advocates could agree on was that obturation was headed in the direction of sealer based techniques rather than the mechanical packing and melting of gutta percha. This made sense from both the technical and science sides.

Dr Ken Koch received both his D.M.D. and Certificate in Endodontics from the University of Pennsylvania School of Dental Medicine. He is the founder and past director of the new program in Postdoctoral Endodontics at the Harvard School of Dental Medicine. In addition to having maintained a private practice limited to endodontics, Dr Koch has lectured extensively worldwide and is the author of numerous articles. Dr Koch is a co-founder of Real World Endo. A diplomate of the American Board of Endodontics, and a member of the College of Diplomates, Dr Dennis Brave received his DDS degree from the Baltimore College of Dental Surgery, University of Maryland and his Certificate in Endodontics from the University of Pennsylvania. Along with having authored numerous articles on endodontics, Dr Brave is a co-founder of Real World Endo. For more information, please visit www.realworldendo.com.

Clinical

Figure 1:
EndoSequence BC
Sealer

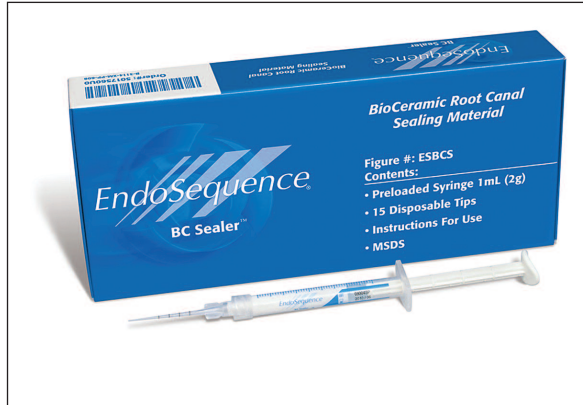
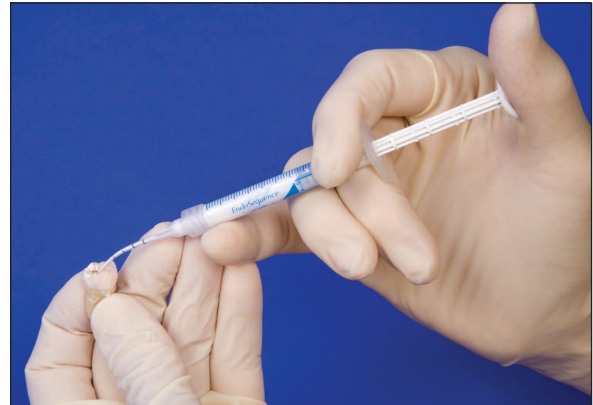

Figure 2: The tip of the syringe should be inserted into the canal no deeper than the coronal one third



It is also very interesting to see how the two materials differed. The resins were shown to have a good seal between the sealer and the gutta percha cone but their seal to the canal wall was questionable. The glass ionomer cements, on the other hand, displayed an excellent seal to the canal wall but their seal to the gutta percha was less than ideal. So as the 20th century came to a close, we still found ourselves searching for a technique that could consistently deliver a true monobloc obturation (Koch, Brave, 2006).

Activ GP obturation is, in fact, a single cone technique that requires a minimal amount of sealer, rather than the excess that is utilized in other methods. This is because the system is precision-based. As previously mentioned, precision-based endodontics requires accuracy between the file and the master cone. Similar to the regular EndoSequence gutta percha, all Activ GP points are laser verified (and calibrated) to precisely match the preparations made by the .04 or .06 tapered EndoSequence file system. The precision matching of the primary cone to the preparation (endodontic synchronicity) is very important with any single cone technique because the accuracy of the cone fit to the preparation minimizes the amount of sealer and any dimensional change. Although dimensional change can occur with all sealers, glass ionomer is very stable and does not shrink. Furthermore, due to the predictability of shape associated with constant tapers, it may be stated that a true single cone technique should be accomplished with a constant tapered preparation such as a .04 or .06. A variable taper technique is not recommended because its lack of shaping predictability (and its corresponding lack of reproducibility) will lead to a less than ideal cone fit. This lack of endodontic synchronicity is why all variable taper preparations are associated with thermoplastic techniques.

While glass ionomer has been a huge help in establishing a true single cone filling technique, there has always been practitioners who question the handling characteristics of glass ionomer. While respecting those questions about handling characteristics, the obturation equation has further changed with the introduction of a new material – bioceramics. This new bioceramic technology is the basis of EndoSequence BC Sealer. But, before we discuss how this specific sealer is changing obturation, we need to address some of the merits associated with bioceramics.

The first question we need to ask ourselves is, 'what are bioceramics?' Bioceramics are ceramic materials specifically designed for use in medicine and dentistry. They include alumina and zirconia, bioactive glass, glass ceramics, coatings and composites, hydroxyapatite and resorbable calcium phosphates, and radiotherapy glasses (Best, Porter, Thian, Huang, 2008; Dubok, 2000; Hench, 1991).

There are numerous bioceramics currently in use in both dentistry and medicine, although more so in medicine. Alumina and zirconia are among the bioinert ceramics used for prosthetic devices. Bioactive glasses and glass ceramics are available for use in dentistry under various trade names. Additionally, porous ceramics such as calcium phosphate-based materials have been used for filling bone defects. Even some basic calcium silicates such as ProRoot MTA (Dentsply) have been used in dentistry as root repair materials and for apical retrofills.

However, we must ask ourselves another question, 'what are the advantages of bioceramics in dental applications?' Clearly the first answer is related to physical properties. Bioceramics are exceedingly biocompatible, non-toxic, do not shrink, and are chemically stable within the biological environment. Secondly (and this is very important in endodontics) bioceramics will produce little, if any, inflammatory response if an over fill occurs during the obturation process or in a root repair. A further advantage of the material itself is its ability (during the setting process) to form hydroxyapatite and ultimately a bond between dentin and filling materials.

While the properties associated with bioceramics make them very attractive to dentistry, in general, what would be their advantage if used as an endodontic sealer? From our perspective as endodontists, some of the advantages are: enhanced biocompatibility, possible increased strength of the root following obturation, high pH (12.8) during the setting process which is strongly anti-bacterial, sealing ability, and ease of use (Hichman, 1990).

The introduction of EndoSequence BC Sealer (Figure 1) allows us, for the first time, to take advantage of all the benefits associated with bioceramics but to not limit its use to merely root repairs and apical retrofills. This is possible because of recent nanotechnology developments (the particle size of BC Sealer is so fine, it can actually be used with a .014 capillary tip). When viewed in the overall context of obturation techniques, EndoSequence BC Sealer is a game changer.

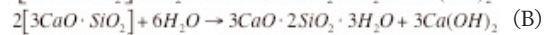
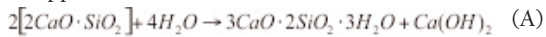
Furthermore, this material has been designed as a non-toxic calcium phosphate silicate cement that is easy to use as an endodontic sealer. In addition to its excellent physical properties, the purpose of BC Sealer is to improve the convenience and delivery method of an excellent root canal sealer while simultaneously taking advantage of its bioactive characteristics (it utilizes the water inherent in the dentinal tubules to drive the hydration reaction of the material, thereby shortening the setting time). Dentin is composed of approximately 20% (by volume) water (Pashley, 1996) and it is this water which initiates the

setting of the material and ultimately results in the formation of hydroxyapatite.

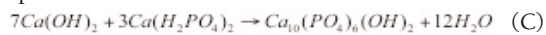
EndoSequence BC sealer setting reactions

The calcium silicates in the powder hydrate to produce a calcium silicate hydrate gel and calcium hydroxide. The calcium hydroxide reacts with the phosphate ions to precipitate hydroxyapatite and water. The water continues to react with the calcium silicates to precipitate additional gel-like calcium silicate hydrate. The water supplied through this reaction is an important factor in controlling the hydration rate and the setting time as following:

The hydration reactions (A, B) of calcium silicates can be approximated as follows:



The precipitation reaction (C) of calcium phosphate apatite is as follows:



For clinical purposes, the advantages of premixed endodontic cement (sealer) should be obvious. In addition to a significant saving of time and convenience, one of the major issues associated with the mixing of any cement, or sealer, is an insufficient and non homogenous mix. Such a mix may ultimately compromise the benefits associated with the material. Keeping this in mind, BC Sealer has been designed as a premixed bioceramic sealer that hardens only when exposed to a moist environment (such as that produced by the dentinal tubules).

The technique with this material is straightforward. Simply remove the syringe cap from the EndoSequence BC Sealer syringe. Then attach an intra canal tip of your choice to the hub of the syringe. The intra canal tip is flexible and can be bent to facilitate access to the root canal. Also, because the particle size has been milled to such a fine size, a capillary tip (such as a .014) can be used to place the sealer.

Following this procedure, insert the tip of the syringe into the canal no deeper than the coronal one third. (Figure 2). Gently and smoothly dispense a small amount (1-2 calibration markings) of EndoSequence BC Sealer into the root canal by compressing the plunger of the syringe. Using a #15 hand file or something comparable (such as the master cone), lightly coat the canal walls with the existing sealer in the canal. Then coat the master gutta percha cone with a thin layer of sealer and very slowly insert it into the canal. The synchronized master gutta percha cone will carry sufficient material to seal the apex. The precise fit of the EndoSequence gutta percha master cone (in combination with a constant taper preparation) creates excellent hydraulics and, for that reason, it is recommended that the practitioner use only a small amount of sealer. Furthermore, as with all obturation techniques, it is important to insert the master cone slowly to its final working length. Finally, here's more good news. The glass components in the bioceramic sealer bond to the Activ GP glass ionomer coated cones. So, in essence what we have is a bond to the canal wall as a result of the hydroxyapatite that is created during the setting reaction and we also have a bond between the ceramic particles in the sealer to the ceramic particles in the glass ionomer coated cone (Activ GP). In a sense, the bioceramic cement, with its ease of use, can replace the glass ionomer sealer.

Case studies

The following five cases (see cases studies 1-5 on following pages) evidence the importance of maintaining endodontic synchronicity, particularly when doing a single cone technique. Also, please notice the radiopacity of BC Sealer. It's excellent.

EndoSequence BC Sealer in combination with Activ GP cones creates an excellent single cone obturation technique. But, when we talk about a true single cone technique let's think about what this really means. The easiest way to comprehend this is to compare a single cone technique to carrier based methods. Recently, many in the endodontic community have come to the conclusion that excessive coronal enlargement (of the radicular dentin) can adversely affect the long-term prognosis of a tooth. While various thermoplastic techniques have contributed to the problem of over enlargement of the radicular dentin (and subsequent weakening of the tooth), the recent use of carrier based obturation (both gutta percha and Resilon) has also resulted in wider than ideal orifice enlargement. The rationale behind this is again quite simple. The larger the hole at the top of the canal, the less likely it is to strip (denude) the carrier of gutta percha (or Resilon). This has been one of the challenges associated with carrier based obturation (stripping the carrier at the orifice during insertion) (Koch, Brave, 2006).

Certainly, one can get good obturation results with carrier-based techniques (as with other methods) if done properly, but this issue of stripping a carrier remains a significant one in endodontics. In these techniques, you heat the obturator and then insert it into the tooth, delivering it to a point just shy of the working length. Basically, you are using a hard plastic carrier to deliver heated gutta percha, or resin, into the root canal system. In addition to the concern of stripping (or denuding) the carrier of gutta percha (or resin) when inserted, is the lack of apical control that is the result of using heated gutta percha or resin. This concern about stripping the carrier at the orifice is often addressed by simply making the hole larger at the top of the canal. However, the concept of filling a root canal with a device that you can 'feel' makes sense. It is essentially the same with an Activ GP cone and BC Sealer, but with some differences. Again, think what you are doing. You are, in essence, using a stiff carrier (but one that is actually a stiffer gutta percha cone, not a plastic carrier) to deliver a non-shrinking bioceramic sealer into the root canal system. So while you get the 'feel' of a carrier-based technique, you have the advantage of using gutta percha as a carrier to deliver sealer. After all, it is the sealer that creates the seal in obturation, not heated gutta percha (which shrinks significantly when cooled). Additionally, post-preparation will be a lot easier because you are now removing gutta percha not cutting plastic. It just makes sense!

Retreatment of bioceramics

Bioceramic sealer cases are definitely retreatable yet the issue of retreating these cases (and all the associated misinformation) is not unlike that of glass ionomer. Historically there has been confusion about retreating glass ionomer endodontic cases (glass ionomer sealer is

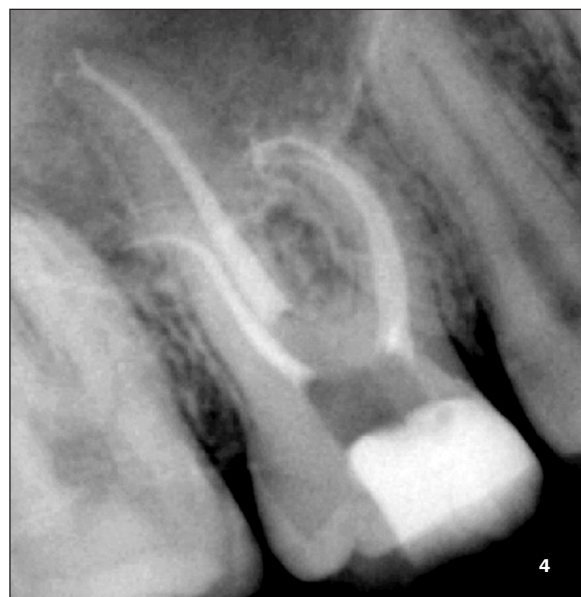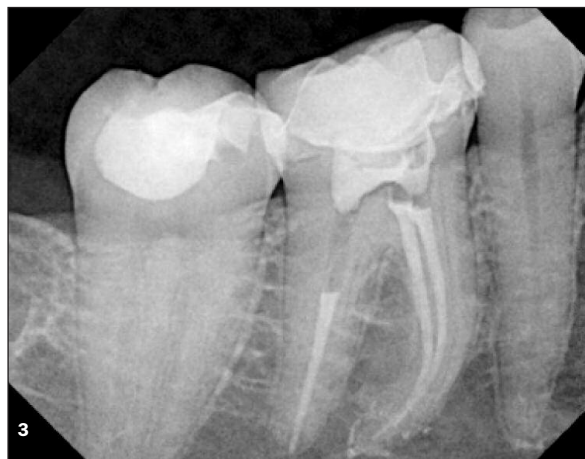
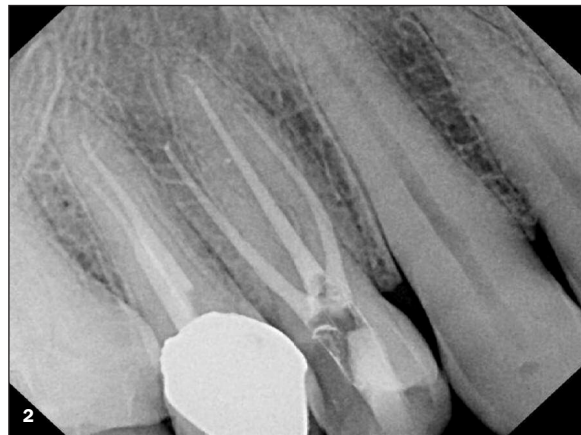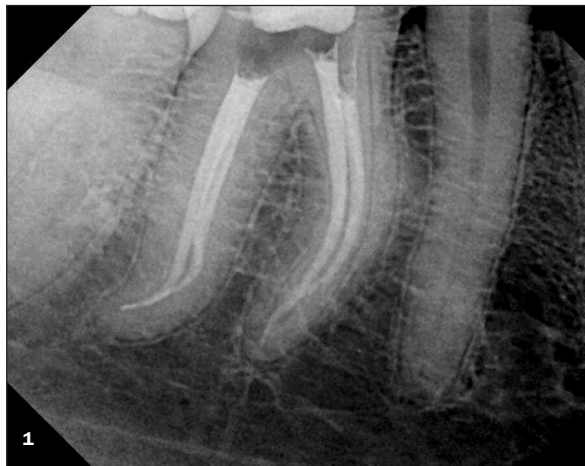Clinical

Case 1: Four canal mandibular molar (courtesy of Dr Ali Nasseh)

Case 2: Three rooted maxillary premolar (courtesy of Dr Ali Nasseh)

Case 3: Mandibular molar with a large mesial curvature (courtesy of Dr Ali Nasseh)

Case 4: Maxillary molar with obturated palatal delta demonstrating how BC Sealer can fill three dimensionally (courtesy of Dr Alex Fleury)



definitely retreatable when used as a sealer (Friedman, Moshonov, Trope, 1993)) and, similarly, there has been confusion concerning the retreatability of bioceramics. The key is using bioceramics as a sealer, not a filler. This is why endodontic synchronicity is so important and again, why the use of constant tapers makes so much sense (it minimizes the amount of endodontic sealer thereby facilitating retreatment).

The technique itself is relatively straightforward. The key in retreatting bioceramic cases is to use an ultrasonic with a copious amount of water. This is particularly important at the start of the procedure in the coronal third of the tooth. Work the ultrasonic (with lots of water) down the canal to approximately half its length. At this point, add a solvent to the canal (chloroform) and switch over to an EndoSequence file (#30 or 35 / .04 taper) run at an increased rate of speed (1,000rpm). Proceed with this file, all the way to the working length, using solvent when indicated. An alternative is to use hand files for the final 2-3mm and then follow the gutta percha removal with a rotary file to ensure synchronicity.

Case 6 demonstrates the retreatment of BC Sealer.

Bioceramics as a root repair material

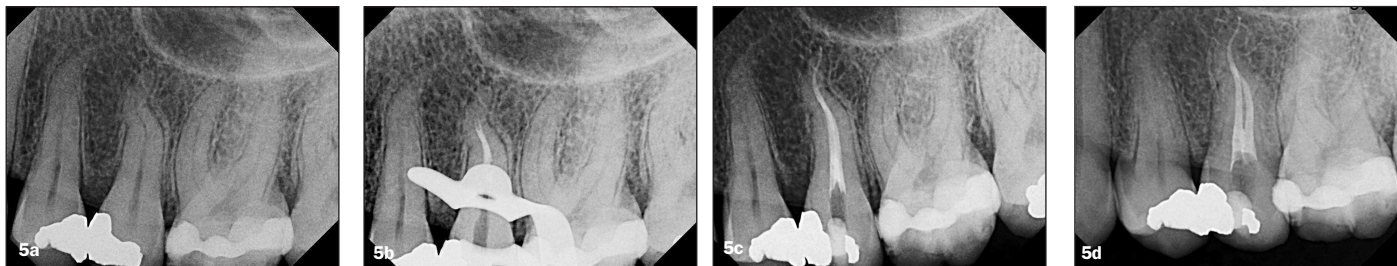We are all familiar with the success of MTA as a root repair and apico retrofilling material. Furthermore, we realize that it is a modified Portland cement and because of such an origin, it has some limitations in terms of handling characteristics. It does not come premixed (and therefore must be mixed by hand), is difficult to use on retrofills, and has such a large particle size that it cannot be extruded through a small syringe. Yet it has a number

of favorable characteristics, including a pH of 12.5 which is anti-bacterial. However, the game has also changed in terms of root repairs and apico retrofills.

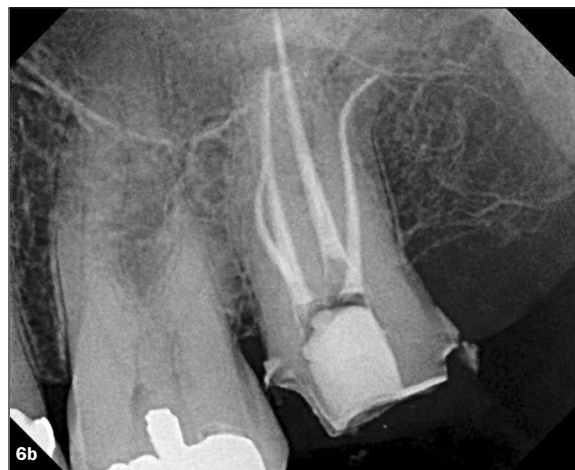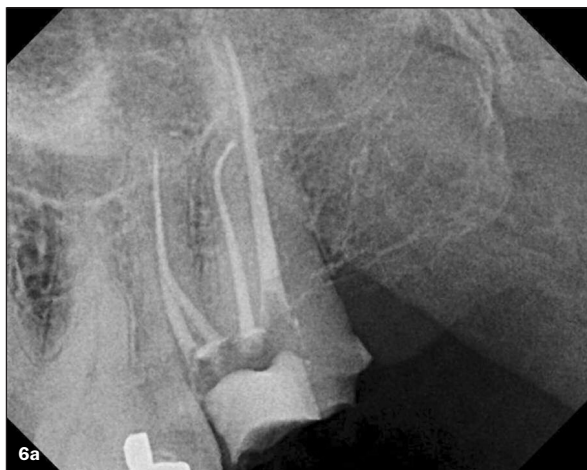The game changer is the new EndoSequence Root Repair material, which comes premixed in a syringe just like BC Sealer. This is a tremendous help not just in terms of assuring a proper mix but also in terms of ease of use. We now have a root repair material with an easy and efficient delivery system.

Actually, EndoSequence Root Repair material has been created as a white premixed injectable cement for both permanent root canal repairs and apico retrofills. It is an insoluble, radiopaque, and aluminum-free material based on a calcium phosphate silicate composition. The setting and hardening reactions of this material also require the presence of water from the tissue or dentin tubules. As a bioceramic cement, the advantages of this new repair material are (again) its high pH (pH >12.5), high resistance to washout, no-shrinkage during setting, excellent biocompatibility, and superb physical properties. In fact, it has a compressive strength of 50-70MPa, which is similar to that of current root canal repair materials, ProRoot MTA (Dentsply) and BioAggregate (Diadent). However, a significant upgrade with this material is its particle size that allows the premixed material to be extruded through a syringe rather than mixing by hand and then placement with a hand instrument.

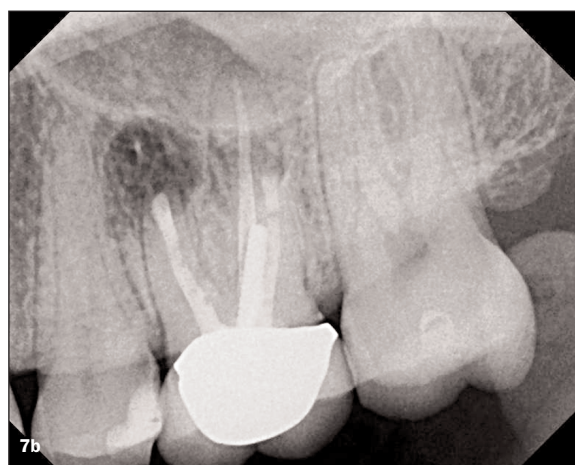
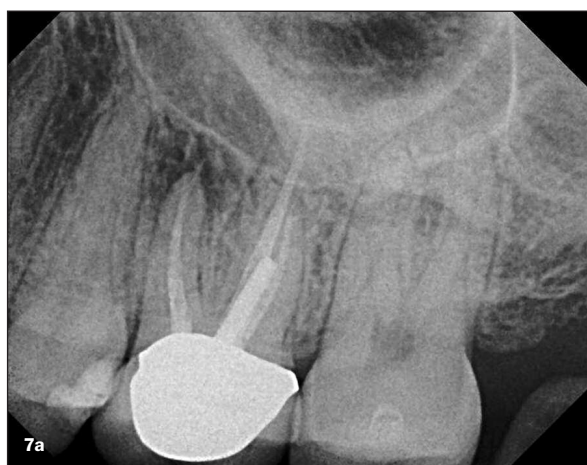Clinical




Case 5: Maxillary premolar case demonstrating the initial placement of BC Sealer (a,b) and then the final placement of the single cones (c,d) (courtesy of Dr Ali Nasseh)



Case 6: Pre- and post-op X-rays of a case initially obturated with Activ GP and BC Sealer and then retreated and obturated with the same technique. Courtesy of Dr Ali Nasseh, Boston



Case 7: Pre- and post-operative X-rays of a surgical case filled with a bioceramic root repair material (Endo Sequence root repair material)

In this article (part one of a two part series), we have introduced a new bioceramic sealer (EndoSequence BC Sealer) that when combined with Activ GP cones offers an exciting new obturation technique. Additionally, we have discussed the benefits associated with medical grade bioceramics as a root repair material. Part two of this series will show surgical cases and other indications for use of this material. The excitement that has been generated for bioceramic technology in both obturation and surgical application is a result of the physical properties associated with it, as well as the incredible ease of use. We now have a true, three-dimensional single cone technique that will allow a much greater percentage of dentists to get outstanding obturation results. Furthermore, we now have a far more expedient way of repairing root defects and filling retro preparations. Bioceramic technology is a game changer! 

References

Best S.M., Porter A.E., Thian E.S., Huang J., (2008) Bioceramics: Past, Present and for the Future, *Journal of the European Ceramic Society* 28: 1319-13

Dubok VA, (2000) Bioceramics Yesterday, Today Tomorrow, *Powder Metallurgy and Metal Ceramics*, 39(7-8)

www.realworldendo.com

Koch K, Brave D (2006) A New Endodontic Obturation Technique *Dentistry Today* 25(5): 102-107

Friedman S, Moshonov J, Trope M, (1993) Residue of gutta percha and a glass ionomer sealer following root canal retreatment, *Intl Endo Jour*, 26(3): 169-172

Fransen JN, He J, Glickman G et al. (2008) Comparative Assessment of Activ GP /Glass Ionomer Sealer, Resilon/Epiphany, and Gutta-Percha/AH Plus Obturation: A Bacterial Study *J Endo* 34(6): 725-727

Hench L., (1991) Bioceramics: From Concept to Clinic, *Journal Amer Ceram Soc* 74(7): 1487-1510

Hichman K., *Bioceramics*, April 1990

<http://www.csa.com/doscoveryguides/archives/bceramics.php#editor>

Koch, K, Brave D, (2009) A New Day has Dawned: The Increased Use of Bioceramics in Endodontics *Dentaltown*

Pashley DH, (1996) Dynamics of the Pulp Dentin Complex, *Crit Rev Oral Biol Med* 7(2): 104-133

Russell GS, Mineo P, et al. (2007) A Fluid Filtration Comparison of Gutta-Percha Versus Activ GP, A New Root Canal Obturation System *J Endo* 33(3): 355